



The Fetal  
Medicine Foundation

137 Harley Street, London W1G  
6BG

Tel: +44 20 7034 3070 Fax: +44 20  
7034 3071

Email:  
fmfcertification@fetalmedicine.com

Wolfgang Moroder  
Via Rezia, 64  
Ortisei BZ  
39046  
Italy

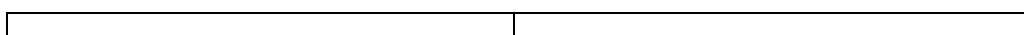
Oct 11, 2011

FMF ID: 17976

# Measurement of the facial angle

Dear Wolfgang Moroder,

Thank you for submitting your logbook of 3 images. I examined each image for the following criteria: magnification (head and thorax), mid-sagittal view, line on the upper surface of the palate, upper corner point, and line on the forehead (see table below).



<b>Criteria</b>	<b>Image number</b>		
	<b>1</b>	<b>2</b>	<b>3</b>
Magnification	✓	✓	✓
Mid-sagittal view	✓	✓	✓
Line on the palate	✓	✗	✓
Upper corner point	✓	✗	✓
Line on the forehead	✓	✓	✗

Legend: ✓ = pass    ✗ = fail    -- = not possible to assess

- In 1 of your images the line on the upper surface of the palate is not placed correctly.
- In 1 of your images the two lines do not meet in the upper corner of the anterior aspect of the maxilla.
- In 1 of your images the line on the forehead is not placed correctly.

Your images are satisfactory. Your software license will include the assessment of **the facial angle** in the risk calculation for chromosomal abnormalities and your name will appear on the list of sonographers certified for assessment of the facial angle.

Best wishes,

Olga Torres Khoury